

Original Article

Changes in bone mineral density and bone turnover markers in patients undergoing hematopoietic stem cell transplant

Aditi Pandit, M. K. Garg, N. Kotwal¹, K. S. Brar¹, Abhay Gundgurthi¹, A. K. Sharma², Sanjeevan Sharma²

Commandant, Military Hospital, Shillong, Meghalaya, Departments of ¹Endocrinology and ²Hematology, Army Hospital Research and Referral, New Delhi, India

ABSTRACT

Introduction: Hematopoietic stem cell transplant (HSCT) is frequently complicated by endocrine abnormalities and loss of bone mass. This prospective study was conducted to evaluate the bone loss post-HSCT. **Materials and Methods:** A total of 50 patients was evaluated pretransplantation, and 25 had HSCT (17 males, 8 females; 19 allogenic, 6 autologous). Bone mineral density (BMD) and bone markers were measured at baseline, 3–6 months and 12 months. **Results:** The mean age and body mass index were 25.1 ± 16.3 years and 19.4 ± 4.5 kg/m², respectively. There were 15 adults (60%), and 10 adolescents (40%). There was a significant decline in BMD from the baseline at total femur (-8.7% ; $P < 0.0001$), femoral neck (-5.0% ; $P = 0.003$), femoral trochanter (-6.0% ; $P = 0.001$), and Ward's triangle (-9.9% ; $P < 0.0001$) at 6 months posttransplantation. From the 6 months to 12 months, there was a significant improvement in BMD at above sites except at Ward's triangle. The decline in BMD was nonsignificant at the whole body (-0.3% , $P = 0.748$) and the lumbar spine (-2.7% , $P = 0.130$) at 6 months posttransplant. Younger patients with allogenic graft and steroid use are more likely to have significant loss of BMD at hip posttransplant. Serum osteocalcin decreased, and N-telopeptide increased at 3–6 months, which return to baseline at 1-year posttransplant. **Conclusions:** A significant bone loss is observed at 6 months in patients with post-HSCT. The bone loss occurs predominantly at cortical bone. There is recovery of bone mass at 12 months posttransplant except at Ward's triangle. Bone loss after HSCT is multifactorial.

Key words: Bone markers, bone mineral density, hematopoietic stem cell transplant

INTRODUCTION

Hematopoietic stem cell transplant (HSCT) is the treatment of choice for many hematological diseases, and the number of long-term survivors has increased remarkably over recent decades. HSCT is frequently complicated by endocrine abnormalities; and loss of bone mass is well documented as a sequel to HSCT.^[1] Previous studies have reported a 5–15% loss in the bone mineral density (BMD) at the lumbar spine (LS) and the femoral neck within 1-year after

HSCT.^[2–5] The pathogenesis of transplantation-related bone loss is multifactorial and is not completely understood. The underlying disease itself, primary hypogonadism, irradiation, steroids and posttransplant immunosuppressant may all contribute to bone loss.^[6,7] With this in hindsight, we conducted this study to evaluate the bone loss in patients undergoing HSCT and various factors affecting it. We hypothesize that patients undergoing HSCT will have significant loss of BMD due to increase in bone resorption and decrease in bone formation. To the best of our knowledge, there is no data available on bone loss post-HSCT in the Indian population.

MATERIALS AND METHODS

This prospective study was conducted at a tertiary care center. All patients irrespective of the etiology were enrolled in the study prior to transplant. Among

Access this article online

Quick Response Code:



Website:
www.ijem.in

DOI:
10.4103/2230-8210.152785

Corresponding Author: Prof. M. K. Garg, Military Hospital, Shillong - 793 001, Meghalaya, India. E-mail: mkgargs@gmail.com

these 50 patients 10 died before HSCT, 7 patients were not transplanted (reasons: Relapse or patient choice), 3 patients lost to follow-up, 3 patients still waiting for HSCT and 2 patients were recently transplanted (posttransplant duration <1-month) hence, were not included in analysis. Rest of 25 patients were included in the study. Indication for HSCT was aplastic anemia (5), multiple myeloma (5), thalassemia major (4), acute lymphoblastic leukemia (ALL) (4), myelodysplastic syndrome (3), chronic myeloid leukemia (2), acute myeloid leukemia (1), and progressive systemic sclerosis (1). Underlying hematological diseases were treated according to the prevailing guidelines. Preparative regimen consisted of myeloablative regimen using "BUCY" protocol (busulfan – 16 mg/kg, cyclophosphamide – 120 mg/kg). Patients with multiple myeloma received melphalan (180 mg/m²). Aplastic anemia patients received anti-thymocyte globulin. Acute lymphoblastic leukemia patients were treated with prophylactic cranial irradiation (12 Gy). Post-HSCT cyclosporine-A (5 mg/kg/day) was used for primary graft versus host disease (GVHD) prophylaxis. GVHD was treated with steroids and another immunosuppressant as indicated. All patients were planned for evaluation before HSCT, at 3–6 months and at the end of 1-year. All 25 patients were available for evaluation at 6 months. At 1-year, only 20 patients could be evaluated because during 6–12 months 3 patients died, one had a relapse of ALL and planned for re-HSCT and one lost to follow-up.

All patients underwent clinical evaluation. Blood samples were collected in fasting state at 0800 h for biochemical tests (fasting and postprandial blood glucose, lipid profile, renal and liver function tests). Serum osteocalcin was measured by ELISA kit (Cat No. 8002, Quidal, USA) to assess bone formation. Its sensitivity was 0.45 ng/L with range of detection 2–32 ng/L. Serum N-terminal telopeptide (Cat No. 504836, Wampole, Teco) was used as a marker of bone resorption (sensitivity 3.2 nmol/L, range 5–40 nmol/L). Inter assay and intra assay coefficient of variation were 5–10%. These were measured at baseline, at 3–6 months and at the end of 12 months.

Bone mass was assessed by dual energy X-ray absorptiometry (DXA). DXA scans were performed on Hologic QDR-4500 densitometer (Hologic, Bedford, MA, USA) machine (fan array beam). All patients underwent BMD of the hip, LS and the whole body. Daily quality control was performed on the phantom spine with coefficient of variation of 1.08% for hip and 1.2% for the LS. The BMD were performed by the same technician and was repeated on the same machine. Informed consent was taken in all patients or parents if the patient was <18 years.

Ethical clearance was obtained from institutional ethical committee for the study.

Statistical analysis was carried out using software program SPSS version 20.0. (SPSS Inc. Chicago, USA) Data were presented as mean ± standard deviation, or number (%) unless specified. All paired parametric data were analyzed by paired *t*-test. Effects of various nonparametric parameters on change of BMD were compared using independent Student's *t*-test. A *P* < 0.05 was considered as statistically significant.

RESULTS

In this prospective study, 25 patients were studied who have undergone HSCT. Basic characteristics of these patients are given in Table 1. All patients were receiving calcium and Vitamin D, hence data were not included. Serum calcium and phosphates were normal in all cases, and 25OHD levels were 27.9 ± 14.5 ng/mL. Aplastic anemia (20%), multiple myeloma (20%), thalassemia major (16%), and ALL (16%) were the most common hematopoietic disorders in the study group. All patients received cyclosporine as part of GVHD prophylaxis. Two patients received tacrolimus and mofetil mycophenolate due to cyclosporine toxicity. GVHD occurred in 6 patients (24%). Out of these 6 patients, 2 patients had acute GVHD and died, remaining patients had chronic GVHD.

Bone mineral density declined significantly at all sites (total, femur neck (FN), trochanter and Ward's triangle) of the hip at 6 months when compared to baseline. However, BMD recovered at 1-year at these sites except at Ward's triangle. There was 5–9.9% decline in BMD at hip at different sites at 6 months from baseline. There was no significant change in BMD at lumbar spine and whole body at 6 or 12 months [Table 2 and Figure 1]. Younger patients (<18 years) had significant higher bone loss at neck femur as compared to older patients at 6 months. Similarly, patients who had allogeneic graft or were on steroid had

Table 1: Basic characteristics

Parameters	Results (%)
Age (years)	25.1±16.3 (3–62), Adolescents-10 (40), Adults-15 (60)
Sex	Male: 17 (68); Female: 8 (32)
BMI	19.4±4.5 (kg/m ²)
Type of BMT	Allogeneic-19 (76), Autologous-6 (24)
Pretransplant Immunosuppression	BUCY-17 (68), Fludarabine-4 (16), Melphalan-4 (16)
Posttransplant Immunosuppression	Cyclosporine-18 (70), Tacrolimus-1 (3.8), Mofetil mycophenolate-1 (3.8)
GVHD	Present-6 (24), Absent-19 (76)
Steroid therapy	13 (52), Cumulative dose 1480±1201 mg
Duration after BMT	6 months-25 (100) 12 months-20 (80)

BMI: Body mass index. GVHD: Graft versus host disease

Table 2: BMD (g/cm²) at various sites and bone markers pre and post-HSCT

Parameters	Pre-HSCT versus 6 months (n=25 patients)			Pre-HSCT versus 12 months (n=20 patients)		
	Pre-HSCT	6 months (%)	P	Pre-HSCT	12 months (%)	P
Femur total	0.884±0.221	0.807±0.204 (-8.7)	<0.0001	0.861±0.217	0.847±0.212 (-1.1)	0.380
Neck femur	0.785±0.173	0.743±0.163 (-5.0)	0.003	0.761±0.171	0.752±0.161 (-0.8)	0.499
Femur trochanter	0.671±0.127	0.625±0.106 (-6.0)	0.001	0.651±0.129	0.628±0.112 (-2.4)	0.095
Ward's triangle	0.711±0.175	0.638±0.168 (-9.9)	<0.0001	0.685±0.168	0.619±0.152 (-8.9)	0.001
Lumbar spine	0.804±0.192	0.781±0.196 (-2.7)	0.130	0.806±0.197	0.802±0.212 (-0.5)	0.862
Whole body	1.019±0.229	1.015±0.214 (-0.3)	0.748	1.011±0.228	1.016±0.195 (1.6)	0.701
Osteocalcin (ng/L)	28.0±2.3	25.0±2.8	<0.0001	27.5±2.0	27.1±2.7	0.525
Telopeptide (nmol/L)	29.2±3.8	39.4±7.5	<0.0001	29.3±4.1	30.3±5.4	0.231

BMD: Bone mineral density, HSCT: Hematopoietic stem cell transplant

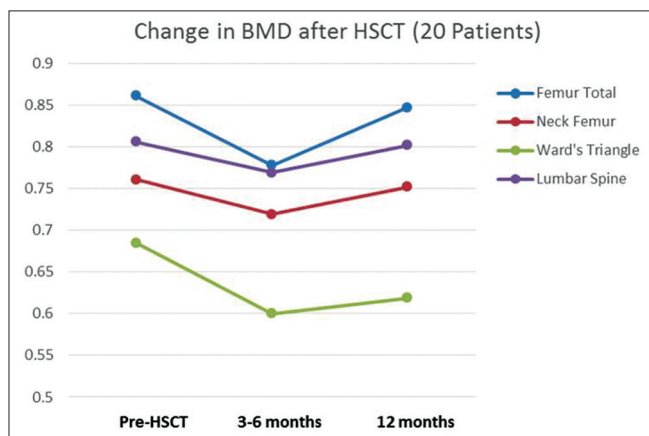


Figure 1: Change in bone mineral density pre-hematopoietic stem cell transplant (HSCT), 3-6 months and 12 months after HSCT among 20 patients who completed 12 months of follow-up

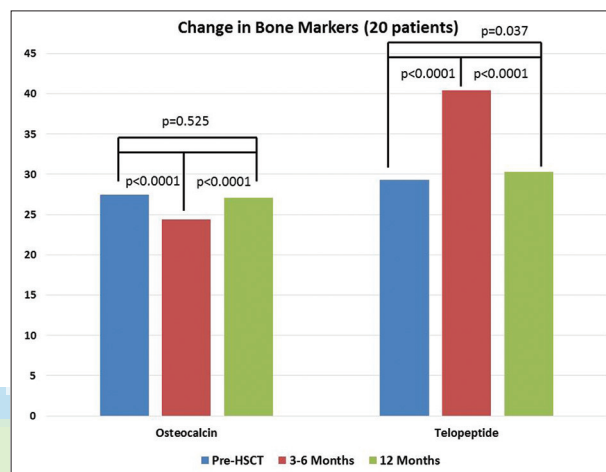


Figure 2: Change in bone markers pre-hematopoietic stem cell transplant (HSCT), 3-6 months and 12 months after HSCT among 20 patients who completed 12 months of follow-up

significantly more decrease in percent BMD at hip. BMD changes with immunosuppressive drugs were similar to those between autologous versus allogeneic transplant as patients who received autologous graft were not on immunosuppressive therapy. Patients with GVHD received steroid, whereas those without GVHD and autologous transplant did not receive steroid therapy, hence, BMD changes among them were similar to changes with steroid therapy. Gender had no effect on bone loss [Table 3].

Bone formation marker (serum osteocalcin) decreased, and bone resorption marker (N-terminal telopeptide) increased significantly at 6 months among all patients from baseline. These changes reverted back at 1-year and became similar to baseline [Table 2 and Figure 2].

DISCUSSION

Transplantation of hematopoietic stem cells (either from a peripheral or bone marrow source) is being performed in steadily increasing numbers and is now an accepted treatment modality for many hematological and nonhematological diseases. Bone loss is a known long-term complication of HSCT.^[1-5] Young patients who survive

long-term after HSCT, they are confronted with new life long problems if they develop osteoporosis related problems. All the data in the literature are of the western population, and there are well-known ethnic differences in bone mass.^[8] In this prospective study, we have evaluated effect of HSCT on bone mass and bone markers at various sites in Indian patients.

In present study, there was significant bone loss at 6 months at hip region including total femur, FN, femur trochanter and Ward's triangle. This is similar to the finding by Kashyap *et al.*^[9] where the decline in the BMD was prominent at the total hip (approximately 11%) and was the sharpest at 6 months posttransplant (9.3% in the first 6 months and 3.6% in the second 6 months). Kananen *et al.*^[10] studied the effect of pamidronate to prevent bone loss in post-HSCT patients. In the group of patients that did not receive pamidronate post-HSCT, reported a maximal bone loss in the total hip (7.6%) 6 months posttransplant. However, they did not find any recovery of BMD at 12 months posttransplant and they reported a bone loss of 7.8% at 12 months posttransplant compared to baseline at hip. Similar to our study, Kananen *et al.*^[11] reported a recovery

Table 3: Factor affecting change in BMD (%) at 6 months post-HSCT

Parameters	Male (n=17)	Female (n=8)	P	Autologous (n=6)	Allogenic (n=19)	P	Age ≤ 18 years (n=10)	Age >18 years (n=15)	P	Steroid (yes) (n=13)	Steroid (no) (n=12)	P
Femur total	-10.9±5.9	-5.0±10.2	0.110	-2.6±7.7	-11.1±7.2	0.027	-12.8±8.2	-7.0±7.3	0.142	-12.5±7.8	-5.2±6.9	0.036
Neck femur	-6.6±7.5	-2.5±8.9	0.271	2.0±6.3	-7.8±7.1	0.008	-11.2±8.4	-2.5±7.3	0.022	-8.1±8.4	-2.2±7.0	0.095
Femur trochanter	-7.7±6.2	-3.3±11.8	0.280	0.7±10.2	-8.8±6.7	0.021	-11.8±6.7	-3.7±8.6	0.054	-8.3±7.6	-4.0±9.6	0.278
Ward's triangle	-12.8±9.1	-5.3±8.7	0.076	-4.2±6.1	-12.2±9.8	0.039	-14.4±9.7	-8.1±7.8	0.175	-15.8±9.7	-4.5±5.3	0.003
Lumbar spine	-4.5±7.9	1.0±9.7	0.145	-1.6±3.8	-3.1±9.8	0.729	-3.6±7.5	-2.2±8.7	0.706	-3.8±7.7	-1.5±8.9	0.526
Whole body	0.1±7.2	0.8±4.8	0.809	0.2±6.0	0.3±6.8	0.964	-1.1±4.4	2.2±8.6	0.240	-0.8±6.8	1.2±6.4	0.458

Values for those received immunosuppressive therapy or not are similar to data of autologous versus allogenic. BMD: Bone mineral density, HSCT: Hematopoietic stem cell transplant

of total hip BMD from baseline at follow-up at median of 75 months posttransplant. In contrast, the studies by Kashyap *et al.*^[9] and Stern *et al.*^[4] observed no recovery at 12 months posttransplant.

Maximal bone loss at 6 months at FN without recovery were also demonstrated by other studies ranging from 5% to 15%.^[2,10,12-14] The nonrecovery of FN BMD from baseline seen in the above studies is in contrast to the present study. Ebeling *et al.*^[6] found that at 12 months posttransplant, FN BMD decreased by 10%. The mean loss in FN BMD was 11.7% with a nonsignificant decrease in postauto HSCT patients. In another study by Lee *et al.*^[15] in the proximal femur, bone loss was calculated as 8.9% from the baseline to 12 months after HSCT. Gandhi *et al.*^[14] found that FN BMD remained significantly lower than baseline at the femoral neck, with no trend toward recovery at 24 months. However, they reported that maximal bone loss takes place in the first 6 months with no further significant loss occurring in the later months. Schulte *et al.*^[2] demonstrated significant bone loss with nadir FN BMD at 24 months with no recovery to baseline even after 48 months. In contrast, Kananen *et al.*^[11] demonstrated recovery of bone mass in FN BMD by + 4.1% at 75 months post-HSCT. A similar trend was observed at femur trochanter and Ward's triangle by various studies.^[10,12,14] In the follow-up of studies conducted by Välimäki *et al.*,^[12] and Kananen *et al.*,^[11] they showed an increase in the trochanter BMD after a median of 75 months post-HSCT, but other has seen no recovery at Ward's triangle.^[16]

The most interesting observation made in the present study was almost complete recovery at 12 months posttransplant, whereas others have reported partial recovery ranging from 24 to 75 months as discussed above. This can be explained by differences among various studies. Firstly, in the present study only one patient received total body irradiation. TBI is associated with hypogonadism, hypopituitarism that further exacerbates the bone loss.^[9] Also, irradiation directly damages bone cells and enlarges resorption lacunae and to increase osteoclast number and activity without an increase in bone formation, leading to increased bone resorption and bone porosity.^[17] Secondly, patients received mixed type of transplantation – autologous and allogenic graft. Autologous HSCT is known to cause less bone loss in the posttransplant period.^[6] Thirdly, steroid free preparatory regimen was used, and steroid was given only in about half of patients. Steroid is known to affect BMD at lumbar and hip region.^[17] Lastly, GVHD occurred only in 24% patients compared to a higher prevalence in other studies.^[1,2,4,18]

In this study, younger patients had a statistically significant percent change in BMD at hip. This is in coherence to

the findings by Bhatia *et al.*^[18] where they found total body BMD of patients in the pediatric age group was significantly decreased compared to the adult population. The bone loss in the younger population is probably multifactorial where growth hormone deficiency,^[19] low body mass index,^[20] hypogonadism,^[21] direct effect of chemotherapy on bone,^[9] or effect of disease *per se* on bone^[22] may play significant role.

Comparing the effects of HSCT on LS and the proximal femur, the bone loss at the LS and whole body was less dramatic. The baseline total body and LS BMD declined nonsignificantly at 6 months post-HSCT with a trend toward recovery of BMD at 1-year, which is similar to other studies.^[4,12-14] In contrast, others have reported significant decrease in the LS BMD at 12 months post-BMT.^[6,10,23] Complete recovery at LS BMD was observed by Schulte *et al.*^[2] at 48 months posttransplant. Similar findings were reported by Kananen *et al.* at median of 75 months post-HSCT.^[11]

The site specific bone loss is seen across all studies and also in this study that is more pronounced at proximal femur than at LS. The bulk of this loss occurs in the first 6 months that corresponds with high dosage of cyclosporine and glucocorticoids given in the first 6 months for GVHD prophylaxis. The defective osteoblast function in the proximal femur may contribute to the dramatic bone loss at proximal femur.^[24] Differences in the tissue expression of several proteins related in bone metabolism such as bone morphogenetic protein-2, several growth factors, and their receptors may also contribute to it.^[15] Immobilization affects predominantly the cortical bone in the initial periods of rest.^[25] Post-HSCT, these patients are bed bound for 2–4 weeks that could have further contributed to the bone loss at the proximal femur. It is clear that the exact mechanism still needs to be elucidated with further studies.

In the present study, the bone formation marker serum osteocalcin declined significantly at around 3–6 months from the baseline and returned to baseline at 12 months posttransplantation. The bone resorption marker serum N-telopeptide reached its peak at 3–6 months posttransplantation and subsequently returning to almost baseline at 12 months posttransplant. Similar finding has been reported by Baek *et al.*^[26] in which they used serum osteocalcin and C-telopeptide as bone formation and bone resorption markers respectively. However, Välimäki *et al.*^[12] reported that though the bone formation marker (bone alkaline phosphatase) returned to baseline by 6 months, the bone resorption marker (serum C-telopeptide) remained elevated throughout the study duration with a peak at 6 weeks duration. Other studies have reported

nadir osteocalcin levels in the immediate posttransplant period at 3 weeks posttransplantation with recovery to baseline by 3 months and peak C-telopeptide levels at 4 weeks with recovery to baseline at 1-year.^[15,27] This also commensurate with current knowledge that bone markers usually precedes the bone changes. In the present study, also the bone markers may have reached peak earlier, which could have missed as we have measured these markers at 3–6 months. However, still we could show that changes in bone mass during posttransplant period is reflective of both-decreased bone formation and increased bone resorption, and recovery of bone mass is also associated with reversal of changes in bone markers.

The main limitation of the study was heterogeneity with respect to age, gender, pubertal status, diagnosis, and type of transplantation; and sample size was small. However, rarity of the disease and infrequent HSCT did not allow us to select large group. In Indian conditions, long follow-up is also a problem, but we could do 1-year follow-up, and further continuation of the study will help to narrow down the wide dispersion in the results.

CONCLUSIONS

A significant bone loss is observed at 6 months in patients with post-HSCT. It is the highest at Ward's triangle followed by femoral trochanter, femoral neck, total hip, LS and whole body. The bone loss occurs predominantly at cortical bone. There is recovery of bone mass at femoral neck, total hip, LS and whole body with a trend toward recovery at femoral trochanter at 12 months posttransplant except Ward's triangle. Bone loss after HSCT is multifactorial. Younger age, allogenic transplant, immunosuppressive therapy posttransplant, and steroid use are all related to bone loss in patients undergoing HSCT.

BMD should be performed in all patients undergoing HSCT at 1-year posttransplantation to assess the bone health. Most patients who recover from bone loss may not require any therapy. Those patients with persistent low BMD may require long-term follow-up and antiresorptive therapy.

ACKNOWLEDGMENTS

We are grateful to ISBMR for the financial grant for performing bone formation and bone resorption markers.

REFERENCES

1. Abou-Mourad YR, Lau BC, Barnett MJ, Forrest DL, Hogge DE, Nantel SH, *et al.* Long-term outcome after allo-SCT: Close follow-up

- on a large cohort treated with myeloablative regimens. *Bone Marrow Transplant* 2010;45:295-302.
2. Schulte C, Beelen DW, Schaefer UW, Mann K. Bone loss in long-term survivors after transplantation of hematopoietic stem cells: A prospective study. *Osteoporos Int* 2000;11:344-53.
 3. Savani BN, Donohue T, Kozanas E, Shenoy A, Singh AK, Childs RW, *et al.* Increased risk of bone loss without fracture risk in long-term survivors after allogeneic stem cell transplantation. *Biol Blood Marrow Transplant* 2007;13:517-20.
 4. Stern JM, Sullivan KM, Ott SM, Seidel K, Fink JC, Longton G, *et al.* Bone density loss after allogeneic hematopoietic stem cell transplantation: A prospective study. *Biol Blood Marrow Transplant* 2001;7:257-64.
 5. Gundgurthi A, Garg MK, Nair V, Pakhetra R, Das S, Sharma S, *et al.* Endocrine complications after busulphan and cyclophosphamide based hematopoietic stem cell transplant: A single tertiary care centre experience. *Indian J Endocrinol Metab* 2013;17:855-63.
 6. Ebeling PR, Thomas DM, Erbas B, Hopper JL, Szer J, Grigg AP. Mechanisms of bone loss following allogeneic and autologous hemopoietic stem cell transplantation. *J Bone Miner Res* 1999;14:342-50.
 7. Weilbaecher KN. Mechanisms of osteoporosis after hematopoietic cell transplantation. *Biol Blood Marrow Transplant* 2000;6:165-74.
 8. Nam HS, Shin MH, Zmuda JM, Leung PC, Barrett-Connor E, Orwoll ES, *et al.* Race/ethnic differences in bone mineral densities in older men. *Osteoporos Int* 2010;21:2115-23.
 9. Kashyap A, Kandeel F, Yamauchi D, Palmer JM, Niland JC, Molina A, *et al.* Effects of allogeneic bone marrow transplantation on recipient bone mineral density: A prospective study. *Biol Blood Marrow Transplant* 2000;6:344-51.
 10. Kananen K, Volin L, Laitinen K, Alfthan H, Ruutu T, Välimäki MJ. Prevention of bone loss after allogeneic stem cell transplantation by calcium, vitamin D, and sex hormone replacement with or without pamidronate. *J Clin Endocrinol Metab* 2005;90:3877-85.
 11. Kananen K, Volin L, Tähtelä R, Laitinen K, Ruutu T, Välimäki MJ. Recovery of bone mass and normalization of bone turnover in long-term survivors of allogeneic bone marrow transplantation. *Bone Marrow Transplant* 2002;29:33-9.
 12. Välimäki MJ, Kinnunen K, Volin L, Tähtelä R, Löyttyniemi E, Laitinen K, *et al.* A prospective study of bone loss and turnover after allogeneic bone marrow transplantation: Effect of calcium supplementation with or without calcitonin. *Bone Marrow Transplant* 1999;23:355-61.
 13. Buchs N, Helg C, Collao C, Chapuis B, Slosman D, Bonjour JP, *et al.* Allogeneic bone marrow transplantation is associated with a preferential femoral neck bone loss. *Osteoporos Int* 2001;12:880-6.
 14. Gandhi MK, Lekamwasam S, Inman I, Kaptoge S, Sizer L, Love S, *et al.* Significant and persistent loss of bone mineral density in the femoral neck after haematopoietic stem cell transplantation: Long-term follow-up of a prospective study. *Br J Haematol* 2003;121:462-8.
 15. Lee WY, Cho SW, Oh ES, Oh KW, Lee JM, Yoon KH, *et al.* The effect of bone marrow transplantation on the osteoblastic differentiation of human bone marrow stromal cells. *J Clin Endocrinol Metab* 2002;87:329-35.
 16. Schulte CM, Beelen DW. Bone loss following hematopoietic stem cell transplantation: A long-term follow-up. *Blood* 2004;103:3635-43.
 17. Takahashi S, Sugimoto M, Kotoura Y, Sasai K, Oka M, Yamamuro T. Long-term changes in the haversian systems following high-dose irradiation. An ultrastructural and quantitative histomorphological study. *J Bone Joint Surg Am* 1994;76:722-38.
 18. Bhatia S, Ramsay NK, Weisdorf D, Griffiths H, Robison LL. Bone mineral density in patients undergoing bone marrow transplantation for myeloid malignancies. *Bone Marrow Transplant* 1998;22:87-90.
 19. Nussey SS, Hyer SL, Brada M, Leiper AD, Pazianas M. Bone mineralization after treatment of growth hormone deficiency in survivors of childhood malignancy. *Acta Paediatr Suppl* 1994;399:9-14.
 20. Johansson H, Kanis JA, Odén A, McCloskey E, Chapurlat RD, Christiansen C, *et al.* A meta-analysis of the association of fracture risk and body mass index in women. *J Bone Miner Res* 2014;29:223-33.
 21. Kaste SC, Shidler TJ, Tong X, Srivastava DK, Rochester R, Hudson MM, *et al.* Bone mineral density and osteonecrosis in survivors of childhood allogeneic bone marrow transplantation. *Bone Marrow Transplant* 2004;33:435-41.
 22. Klopfenstein KJ, Clayton J, Rossette R, Kerlin B, Termuhlen A, Gross T. Prevalence of abnormal bone density of pediatric patients prior to blood or marrow transplant. *Pediatr Blood Cancer* 2009;53:675-7.
 23. Petryk A, Bergemann TL, Polga KM, Ulrich KJ, Raatz SK, Brown DM, *et al.* Prospective study of changes in bone mineral density and turnover in children after hematopoietic cell transplantation. *J Clin Endocrinol Metab* 2006;91:899-905.
 24. Ebeling PR. Defective osteoblast function may be responsible for bone loss from the proximal femur despite pamidronate therapy. *J Clin Endocrinol Metab* 2005;90:4414-6.
 25. Rittweger J, Simunic B, Bilancio G, De Santo NG, Cirillo M, Biolo G, *et al.* Bone loss in the lower leg during 35 days of bed rest is predominantly from the cortical compartment. *Bone* 2009;44:612-8.
 26. Baek KH, Lee WY, Oh KW, Kim HS, Han JH, Kang MI, *et al.* Changes in the serum growth factors and osteoprotegerin after bone marrow transplantation: Impact on bone and mineral metabolism. *J Clin Endocrinol Metab* 2004;89:1246-54.
 27. Kang MI, Lee WY, Oh KW, Han JH, Song KH, Cha BY, *et al.* The short-term changes of bone mineral metabolism following bone marrow transplantation. *Bone* 2000;26:275-9.

Cite this article as: Pandit A, Garg MK, Kotwal N, Brar KS, Gundgurthi A, Sharma AK, *et al.* Changes in bone mineral density and bone turnover markers in patients undergoing hematopoietic stem cell transplant. *Indian J Endocr Metab* 2015;19:393-8.

Source of Support: ISBMR, **Conflict of Interest:** None declared.